

## **Peste des Petits Ruminants (PPR) outbreak in southern, Tanzania**

Muse, E.A.<sup>1</sup>, Matondo, R.B.<sup>2</sup>, Karimuribo, E.D.<sup>2</sup>, Misinzo, G.<sup>2</sup>, Mellau, L.S.B.<sup>2</sup>, Msoffe, P.L.M.<sup>2</sup>, Albano, M.O.<sup>3</sup> & Gitao, G.C.<sup>4</sup>

<sup>1</sup>Tanzania National Parks, Ruaha National Park, P. O. Box 369, Iringa, Tanzania

<sup>2</sup>Sokoine University of Agriculture, P. O. Box 3000, Morogoro, Tanzania

<sup>3</sup>Veterinary Investigation Centre, P. O. Box 186, Mtwara, Tanzania

<sup>4</sup>University of Nairobi, P.O. Box 29053, Nairobi, Kenya

**Corresponding author:** epaphrasa@gmail.com

### **Abstract**

Peste des petits ruminants (PPR) was first confirmed in Tanzania in 2008, however description of clinical or pathological signs was not carried out although this is important to assist quick identification and reporting of PPR cases by both livestock keepers and field-based animal health workers. A study was therefore conducted to investigate and describe clinical signs and pathological lesions associated with suspected PPR cases in southern Tanzania. It involved history taking and clinical examination of suspected cases of 25 goats and 3 sheep. Post-mortem examination of some cases was performed followed by collection of specimens for histopathological examination. Swabs were also collected for confirmation of PPR by detecting ribonucleic acid using reverse transcription polymerase chain reaction (RT-PCR). Serum samples were analysed using competitive enzyme linked immunosorbent assay (cELISA). Severe depression, high fever, anorexia, muco-pulurent nasal discharge, erosive and necrotic stomatitis, mild diarrhoea and skin nodules were major signs suggestive of PPR. Post mortem examination showed evidence of pneumonia including lung congestion and consolidation. RT-PCR confirmed presence of the PPR virus in samples and serum antibodies showed seroprevalence of 31%.

**Key words:** Morbilli virus, PPR, pneumonia, PPRV, skin nodules

### **Résumé**

La Peste des petits ruminants (PPR) a été confirmée pour la première fois en Tanzanie en 2008, mais la description de signes cliniques ou pathologiques n'a pas été effectuée, bien que ceci soit important pour faciliter l'identification rapide et la notification des cas de PPR par les éleveurs et les agents de santé animale basés sur terrain. Une étude a donc été menée afin de rechercher et de décrire les signes cliniques et les lésions pathologiques associées à des cas présumés de PPR au sud de

la Tanzanie. Elle a impliqué l'anamnèse et l'examen clinique des cas suspects de 25 chèvres et 3 moutons. L'examen post-mortem de certains cas a été effectué, suivi par la collecte d'échantillons pour l'examen histopathologique. Les échantillons ont été prélevés pour la confirmation de la PPR en détectant l'acide ribonucléique en utilisant la transcription inverse de la réaction en chaîne de la polymérase (RT-PCR). Des échantillons de sérum ont été analysés en utilisant l'enzyme concurrentiel lié à l'essai immunoabsorbant (cELISA). La dépression sévère, une forte fièvre, l'anorexie, l'écoulement nasal muco-pulvent, la stomatite érosive et nécrotique, la diarrhée légère et les nodules cutanés étaient les principaux signes évocateurs de la PPR. L'autopsie a montré des signes de pneumonie, incluant la congestion et la consolidation des poumons. La RT-PCR a confirmé la présence du virus de la PPR dans les échantillons et les anticorps sériques ont montré la séroprévalence de 31%.

Mots clés: Virus Morbilli, PPR, pneumonie, PPRV, nodules cutanés

## Background

Recently, PPR broke out in the southern parts of Tanzania in early 2010, threatening a local population of over 13.5 million goats and over 3.5 million sheep (FAO, 2010). Although PPR disease outbreaks in Tanzania have been reported in Northern Tanzania since 2008 (Swai *et al.*, 2009), there has been no description of clinical or pathological manifestation of the disease which is important in guiding livestock keepers and field-based animal health workers to identify and diagnose PPR cases. When a new disease is introduced in a country or an area, it is likely to be confused with other diseases and also lack of laboratory facilities necessitates use of clinical signs for field-based diagnosis. Clear picture on signs and lesions (standard case definition) that could be used to identify a disease are important during disease investigation, disease surveillance and control.

This study was done to describe clinical manifestations and pathological lesions associated with clinical cases as well as confirmation of PPR by detection of virus ribonucleic acid. Findings would help disease control measures and to reduce the disease impacts.

## Literature Summary

Peste des Petits Ruminants (PPR) is an acute, highly contagious and infectious disease specific to small ruminants and small wild stocks (Nussieba *et al.*, 2009a). The disease is caused by

Peste des Petits Ruminants virus (PPRV) classified under Paramyxovirinae, and genus *Morbillivirus* (Chauhan *et al.*, 2009). Transmission of PPR is achieved by direct contact from infected to susceptible animals by close contact or through respiratory and oral routes (Chauhan *et al.*, 2009).

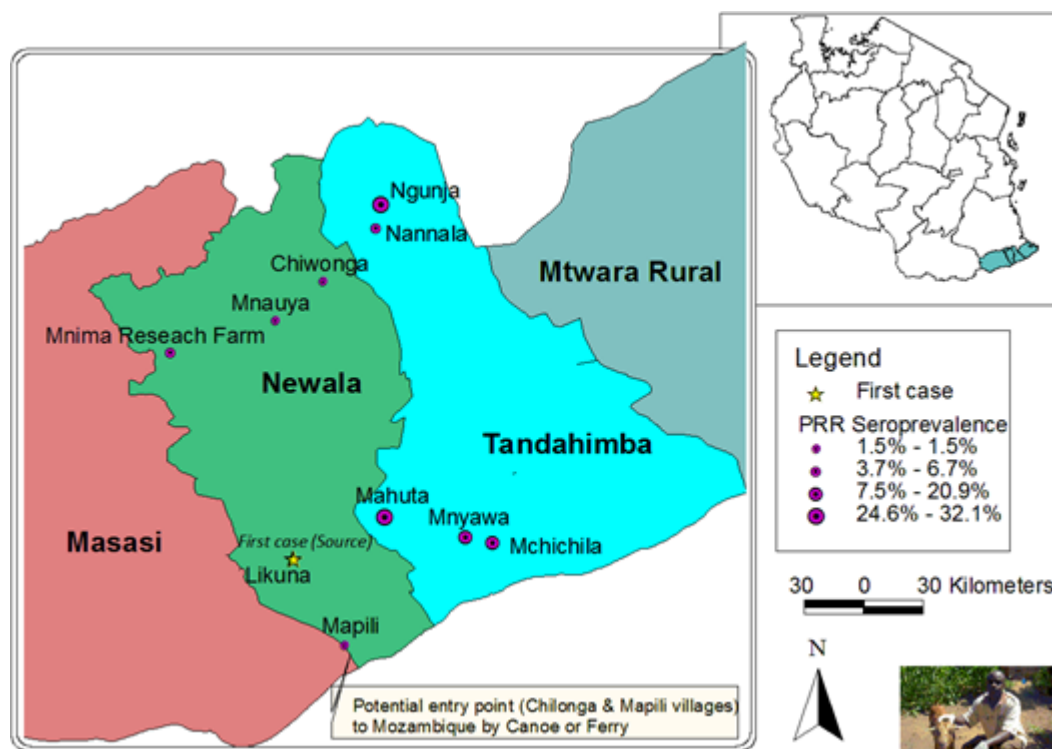
PPRV targets epithelial cells and pneumocytes leading to respiratory lesions include interstitial pneumonia and bacterial bronchopneumonia or fibrinoid pneumonia (Aruni *et al.*, 1998) as well as bronchiointerstitial pneumonia (Nussieba *et al.*, 2009b). The lymph nodes are characterized by oedema (Nussieba *et al.*, 2009b).

The disease is endemic and common in goats and sheep in Asia, China, Middle East, Eastern parts of Europe, West, Central and East Africa (Banyard *et al.*, 2010). Goats are more affected than sheep (Nussieba *et al.*, 2009b) and PPR occurs in an epizootic form with a morbidity of 80-90% and mortality between 50 and 80% (Chauhan *et al.*, 2009). PPR reduces the pastoralist's income generation impacting negatively their livelihoods and food security (Banyard *et al.*, 2010). Women and children depending on small ruminants are even more affected (Kumar *et al.*, 2003).

## Study Description

The study was done in Mkulung'ulu and Bondeni villages, Mahuta ward in Tandahimba district of Mtwara region (Fig. 1), southern Tanzania (Latitude 10°42'22" S and 10°52'22" S, Longitude 39°24'22" E and 39°47'22" E and altitude 100-800 m a.s.l.). Mean total rainfall (600–1000mm), mean monthly temperature (23–27°C) and relative humidity (79–87%). Tandahimba district has human population of 203,837 and 149,945 goats as well as 2,348 sheep. This district borders Mueda district of the Cabo Delgado province of Mozambique.

Village and goat and sheep owners who participated in this study were purposively selected based on the presence of active suspected PPR cases in their flocks. History taking involved questions on introduction of new animals and animal bought from live animal markets; morbidity and mortality; any treatment and its effects; previous similar incidences and clinical signs; grazing system; presence and frequency of veterinary services and any vaccination done. Animals were identified by owners and given case numbers during bio-data taking. Animals were first visually inspected at a distance and environment was examined. Then sick animals were restrained by owners for



**Figure 1. Map showing PPR seroprevalence and introduction of PPR in Newala .**

detailed clinical examinations as well as recording rectal temperature using a clinical thermometer. Among animals clinically examined for PPR signs (33.3 % N=75) goats and (27.3%, N=11) sheep showed signs. Only 28% goats died.

Swabs for virological examination from clinically sick animals (n=30) were collected using sterile swabs and placed in a universal viral transport media (BD, Maryland, USA). The samples were transported chilled on ice to Sokoine University of Agriculture laboratory for analysis. Clinical samples from each animal were pooled together for virological analysis in RT-PCR to confirm presence of PPRV in suspected cases. The RNA extraction was done using a commercial RNA extraction kit then converted to DNA using a reverse transcriptase enzyme at 55°C for 30 minutes. Afterwards, a 350 bp DNA fragment of the nucleoprotein (NP) gene was amplified by PCR with NP3 and NP4 as described by Couacy-Hymann *et al.* (2002). The PCR amplification reaction was carried out in a DNA thermal cycler with an initial denaturation (95°C, 10min), 40 cycles with denaturation (94°C, 30s), annealing (55°C, 30s) and extension (72°C, 30s) and a final extension

(72°C, 7min). Electrophoresis was done to visualize PCR products.

Pathological samples were collected, preserved in 10% neutral buffered formalin and embedded in paraffin wax. Haematoxylin and Eosin staining was done on 5µm thick tissue sections and then examined under light microscope attached to a digital camera and photographs were then taken.

A total of 216 serum samples were collected from goats and sheep in Newala and Tandahimba districts. A monoclonal antibody (MAb) based competitive Enzyme Linked Immunosorbent Assay (cELISA) was used for the detection of antibodies in sera to PPRV using approved competitive ELISA kit as described by Swa *et al.* (2009).

### Research Application

Clinical presentation, glossy and histopathological features, serological and molecular findings suggest that the disease outbreak in southern Tanzania was due to PPR (Muse *et al.*, 2012a, b). The first case was reported in Likuna village, and Mahuta and Ngunja villages had the highest PPR seroprevalence (Fig. 1). Clinical signs observed in sick animals included: high fever (41°C), depression, anorexia, purulent lacrimation, reddening of conjunctiva, matting of the eyelids and nodules all over the body. The source of the infection and spread of PPR was introduction of new animals and contact during communal grazing and housing. The disease shows capability of PPR to move quickly across long distance and large areas due to quick movement of small animals. Small ruminants in southern Tanzania and SADC countries are at high risk from PPR.



Figure 2. Severe ulcers on nostril and lips, eyelids matting and nodular skin lesions in goat.

PPR is a relatively new disease in Tanzania hence the study results will be used to create PPR awareness to different stakeholders including livestock keepers, field officers and veterinarians, local, national and regional governmental authorities. The findings will be used to: i) develop information dissemination materials and programmes including brochures, posters, booklets, newspapers, disease diagnostic manual and TV and radio programmes; ii) strengthen veterinary services like disease diagnosis and surveillance including animal movement control, trans-boundary border posts, Veterinary investigation centres, Research centres and disease reporting system; and iii) advice on vaccination and quarantine. Further studies should focus on disease awareness, socioeconomic impact and preparedness.

### Acknowledgement

We express our gratitude to the project of RUFORUM (RU 2009 GRG 17TADS) for the support. We are very grateful for the staff at the Department of Veterinary Pathology, Sokoine University of Agriculture, Veterinary Investigation Centre in Mtwara and Arusha for facilitation, coordination and their technical support. We also thank staff field officers and farmers for their invaluable contributions in terms of their time and cooperation.

### References

- Aruni, A.W., Lalitha, P.S., Mohan, A.C., Chitravelu, P. and Anbumani, S.P. 1998. Histopathological study of a natural outbreak of Peste des petits ruminants in goats of Tamilnadu. *Small Ruminant Research* 28: 233-240.
- Banyard, C.A., Satya, P., Carrie, B., Chris, O., Olivier, K. and Genevieve, L. 2010. Review global distribution of Peste des petits ruminants virus and prospects for improved diagnosis and control. *Journal of General Virology* 91: 2885-2897.
- Chauhan, H.C., Chandel, B.S., Kher, H.N., Dadawala, A.I. and Agrawal, S.M. 2009. Peste des petits ruminants virus infection in animals. *Veterinary World*, 2(4): 150-155
- Couacy-Hymann, E., Roger, F., Hurard, C., Guillou, J.P., Libeau, G. and Diallo, A. 2002. Rapid and sensitive detection of Peste des petits ruminants virus by a polymerase chain reaction assay. *Journal of Virological Methods* 100: 17-25.
- Diallo, A., Libeau, G., Couacy-Hymann, E. and Barbron, M. 1995. Recent developments in the diagnosis of rinderpest and peste des petits ruminants', *Veterinary Microbiology* 44:307-317
- FAO (Food and Agricultural Organization). 2010. Peste des Petits in Southern Tanzania. <http://coalgeology.com/deadly->

- [animal-virus- peste-des-petits-ruminants-threatens-to-spread-to-southern-africa/8302/](#) Visited 09, April, 2012
- Kumar, S., Vihan, V.S. and Deoghare, P.R. 2003. Economic implication of diseases in goats in India with references to implementation of a health plan calendar. *Small Ruminant Research* 47: 159-164.
- Muse, A.E., Karimuribo, D.E., Misinzo, G., Gitao, C.G. and Albano, O.M. 2012a. Clinico-pathological findings of the 2011 outbreak of Peste des Petits Ruminants (PPR) in Tandahimba district, southern Tanzania. *Research Opinion in Animal and Veterinary Science* 2(4): 256-262.
- Muse, A.E., Karimuribo, D.E., Misinzo, G., Gitao, C.G., Mellau, S.B.L., Msoffe, L.M.P., Swai, S. and Albano, O.M. 2012b. Epidemiological investigation of introduction and factors for spread of Peste des petits ruminants, Southern Tanzania. *Onderstepoort Journal of Veterinary Research* (In press).
- Nussieba, A.O., Ali, A.S., Mahasin, E.A.R. and Fadol, M.A. 2009a. Antibody seroprevalences against Peste des Petits Ruminants (PPR) virus in sheep and goats in Sudan. *Tropical Animal Health Production* 41: 1449-1453.
- Nussieba, N.O., Ali, A.S., Rahman, M.E.A. and Fadol, M.A. 2009b. Pathological, serological and virological findings in goats experimentally infected with Sudanese Peste des Petits Ruminants (PPR) virus isolates. *Journal of General Molecular Virology* 1(1): 1-6.
- Swai, E.S., Kapaga, A., Kivaria, F., Tinuga, D., Joshua, G and Sanka, P. 2009. Prevalence and distribution of Peste des petits ruminants virus antibodies in various districts of Tanzania. *Veterinary Research Communications* 33: 927-936.